CASE REPORT J Pub Health Med Res 2015;3(1):52-54

Pleural Nocardiosis- A Case Report

Rajesh B. P.[1], Akshay M. Hiremath[2]

[1]Associate Professor, [2]Post Graduate Resident, Department of Pulmonary Medicine,
J.J.M. Medical College.Davangere-577004, Karnataka. India.

(Received:05/12/2014, Revised: 01/02/2015, Accepted: 12/03/2015)

Abstract :

Pulmonary nocardiosis (PN) is an infrequent and severe infection due to Nocardia spp., microorganisms that may behave both as opportunists and as primary pathogens.Here is a case report of 75 yr old male patient with pleural nocardiosis with concurrent COPD presenting with pleural effusion who improved with intervention and treatment.domonas, Ciprofloxacin, Azithromycin, antimicrobial agents, Microbial Sensitivity Tests.

INTRODUCTION Pleural involvement is common in pulmonary nocardiosis and was detected in 36% of the cases using computed tomography of chest. In nocardiosis, pleural involvement occurs through direct spread from the chest wall or the lung parenchyma and pleural fluid may be the only source of diagnosis. In the Indian literature, we could find only a few isolated case reports of Nocardia asteroides causing hydropneumotho rax, empyema & pyopneumothorax. Among the Indian studies of nocardiosis, a recent study from Chandigarh9 documented two cases of pulmonary nocardiosis with concomitant pleural involvement (one each of pleural effusion due to Nocardia asteroides and pyopneumo thorax due to Nocardia brasiliensis). We describe here two unusual cases of pleural nocardiosis in adults.

A 75 years male patient poorly built &nourished presentedwith chief complaints of fever, breathlessness, right sided chest pain, cough with scanty expectoration, loss of appetite since 1 month. Patient was having COPD. NO h/o any other co morbid illness.

ON EXAMINATION :

Pulse : 102 per minute

BP:130/80mmhg

Spo2:85% on room air

Respiratory system examination : Signs of right pleural effusion noted.

TLC - 21,290 cells per mm3 HIV1 &2, HBsAg, HCV : non-reactive. LFT- WNL. RBS, UREA, CREATININE- WNL.

Address Correspondence to :
Dr. Akshay M Hiremath
Post Graduate in Pulmonary Medicine
J.J.M.Medical College.Davangere
Email: akshaymh03@gmail.com
Mobile : 9620326244

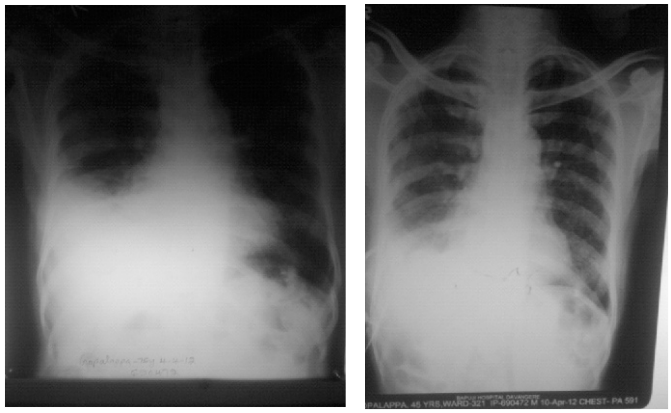

cxr PA view showing R PLEF cxr PA view after ICD

Fig-1

Course in the Hospital :

Diagnostic Aspiration was done. Thick fluid with sediments found. Pleural fluid was exudative. Hence proceeded with Intercostal drainage procedure.

Pleural fluid specimen :

Pleural fluid analysis showed Nocardia Astereroids.

Pleural Fluid AFB STAIN shows:

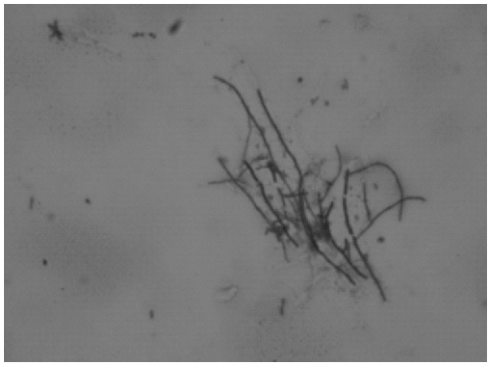

Fig. 2 - Acid fast staining showing acid fast filaments that are 1%acid fast.Done from culture.

Pleural Fluid GRAM'S Staining shows :



Fig 3 : GM staining that shows GM+ve filaments that branch with typical Beaded appearance

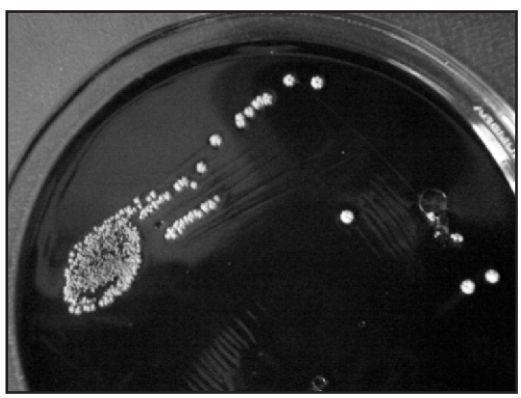

Fig. 4 : Culture From Specimen on Blood Agar - showing chalky white colored colonies after prolonged incubation for 72 hours.



Fig 5 : **Culture from specimen on SDA- Sabourad's Dextrose Agar :** showing chalky white colored colonies

Fig 6 : Culture from Specimen in Brain Heart Infusion Broth- Showing Chalky White Colonies on Surface of Liquid

Treatment : Patient was started on Trimethoprim-sulphamethaxazole (TMP-SMX). Patient improved clinically, drain reduced to less than 100ml by 10 days. ICD removed on 11th day. Patient was regularly followed up for 6 months with same treatment. Patient improved clinically.

Discussion :

Nocardia spp. are aerobic Gram-positive bacteria of the order Actinomycetales. In humans, N. asteroides complex is the predominant pathogen, but there are several other species, including: N. brasiliensis and N. otitidiscaviarum. Pulmonary infection is usually produced by N. asteroides (85%), whereas N. Brasiliensis causes cutaneous and subcutaneous abscesses.

Nocardia species are common natural inhabitants of the soil throughout the world. Pulmonary nocardiosis is usually acquired by direct inhalation of Nocardia spp. from contaminated soil and person- to-person transmission is rare. N. asteroides may be a saprophyte in the skin and in the upper respiratory tract. Respiratory colonization can occur, and in a compromised host it can progress to tissue invasion and dissemination.

Host resistance to infection with Nocardia spp. is thought to depend on functioning phagocytic cells.

Neutrophils limit spread of infection in the early stage of tissue invasion. Activated macrophages and T-lymphocytes prevent dissemination and kill the bacteria . The crucial role of cell-mediated immunity has been proved in experimental in vitro studies; thus, it is not surprising that Nocardia spp. behaves as an opportunist microorganism in an immunocompromisedhost .

Samples are examined by direct microscopic observation of preparations with Gram, acid-fast and

weakly acid-fast stains. Specimens are cultured on blood agar plates, brain-heart infusion agar and

blood-chocolate plates for identification & isolation of organism.

Nocardiaspp. is a slowly growing microorganism that requires a prolonged period of incubation.

Cultures should be maintained for at least 3 weeks before being discarded as negative. On review of literature K. Gowrinath[1], et al form Departments of Tuberculosis and Respiratory Diseases[1] and Microbiology[2], Kasturba Medical College, Manipal (Karnataka), India reported two cases of pulmonary nocardiosis , one case with pyopneumothorax died before diagnosis and other case with effusion showed excellent response with six month of therapy with SMX-TMP.

Nimesh K. Patel, et al from University of Arizona, Department of Medicine.

Tucson, Arizona alsoreported a case which highlights the presence of empyema due to Nocardia cyriacigeorgica infection, an unusual feature of Nocardia pulmonary involvement.

References :

1. Harrisons Text Book of Medicine 18th Edition.
2. Gowrinath K, Sugandhi R.P, Aswini KM, Peralam Y P. Pleural Nocardiosis. Ind J Chest Dis & Allied Sci.2009;51.
3. Patel K, Linda Snyder D.O, Nimesh M.D. Pulmonary Nocardiosis and Empyema in a Patient with Metastatic Neuroendocrine Tumor. Southwest J Pulum Crit Care. 2011; 3.

How to Cite this article :
Rajesh B. P., Pleural Nocardiosis- A Case Report
J Pub Health Med Res, 2015;3(1):52-54

Funding: Declared none
Conflict of interest: Declared none